

» CASE STUDY 205

AmeriGel® under ProFore®

VENOUS INSUFFICIENCY ULCER, LEFT LOWER LEG :

DATE : March 1998

PATIENT : 59 year-old Caucasian female

MEDICAL HISTORY :

A diabetic with CHF, RA, COPD, Osteoporosis, Bronchitis, Hypertension, Anemia, GI bleeding, and prior multiple joint replacements.

Patient "bumped" left calf on a wheelchair. The area exacerbated from a bruise to a large ulceration. The patient was also taking 150 mg Predisone QD. Various wound treatments were employed without any progression, amputation was recommended.

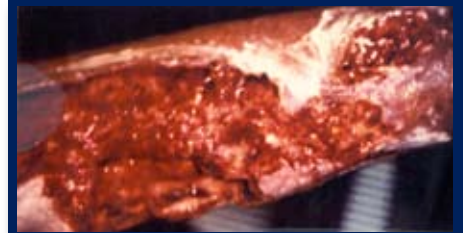TREATMENT :

Daily dressing changes were performed, consisting of cleansing the wound with saline, application of AmeriGel® Wound Dressing, moist saline gauze and covered with ProFore® compression garment.

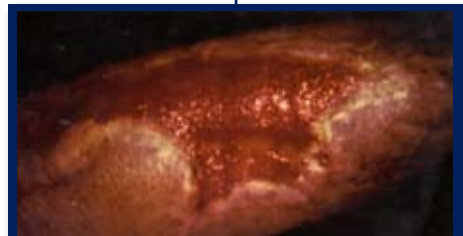RESULTS :

Overall size of wound 200.25cm x 8cm initially, and measured 140.82 cm x 4 cm 6 days later (30% reduction in size). The wound was reduced 88% in 66 days and achieved total wound closure 08/15/98.

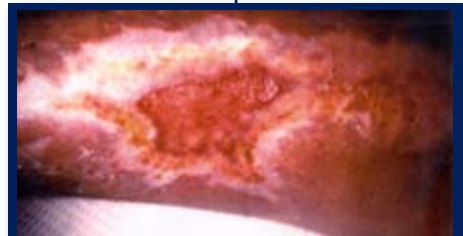
Note: The wound did not require an additional debridement during entire treatment.



» DAY 1 - 03/24/98



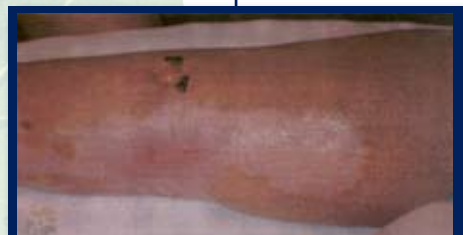» DAY 37 - 04/29/98



» DAY 66 - 05/27/98



» DAY 116 - 07/16/98



» DAY 146 - 08/15/98